

## Uveitis and Acute Myelitis after COVID-19

**Narjes Gouta\*,  
Mariem Mhiri,  
Rihab Ben Dhia,  
Mouna Aissi and  
Mahbouba Frih-Ayed**

Department of Neurology, Fattouma Bourguiba Hospital, Monastir, Tunisia

\*Corresponding author: Narjes Gouta

✉ narjes\_gouta@yahoo.fr

Department of Neurology, Fattouma Bourguiba Hospital, Monastir, Tunisia.

Tel: +21695034905

### Abstract

A number of neurological disorders have been reported to be associated with the novel corona virus (COVID-19) including acute stroke, encephalitis, convulsions, peripheral neuropathy and rarely myelitis. Multiple other symptoms have been reported such as uveitis. In this article we presented the case of a 32-year-old woman who was presented to hospital with proprioceptive ataxic walking, progressive lower limb weakness, urinary retention and visual blur. She had been diagnosed with COVID-19 four days before the appearance of symptoms. Clinical examination showed weakness, hyporeflexia, hypoaesthesia of both lower limbs and intermediate uveitis. The evolution was marked by the total regression of the motor deficit and partial regression of the visual blur after treatment with intravenous methylprednisone. It is important to recognize potential neurologic manifestations and complications of the novel corona virus especially when some of which can be rapidly progressing and require urgent intervention.

**Keywords:** COVID-19; Myelitis; Uveitis

**Received:** January 16, 2022; **Accepted:** February 16, 2022; **Published:** February 23, 2022

**Citation:** Gouta N, Mhiri M, Dhia RB, Aissi M, Frih-Ayed M (2022) Uveitis and Acute Myelitis after COVID-19. J Neurol Neurosci Vol.13 No.1:409

### Introduction

Coronavirus disease 2019 (COVID-19) is an infectious disease caused by a recently discovered coronavirus. The majority of people with COVID-19 experience only mild or moderate symptoms and recover without special treatment. Neurological manifestations and complications of acute and post COVID-19 are common, ranging from mild nonspecific symptoms to severe manifestations such as encephalopathy and myelitis [1]. Acute myelitis is an acute inflammation of gray and white matter leading to muscle weakness and paralysis. In the medical literature only few cases of acute myelitis associated with COVID-19 infection are reported. Uveitis after COVID-19 disease is rarely reported.

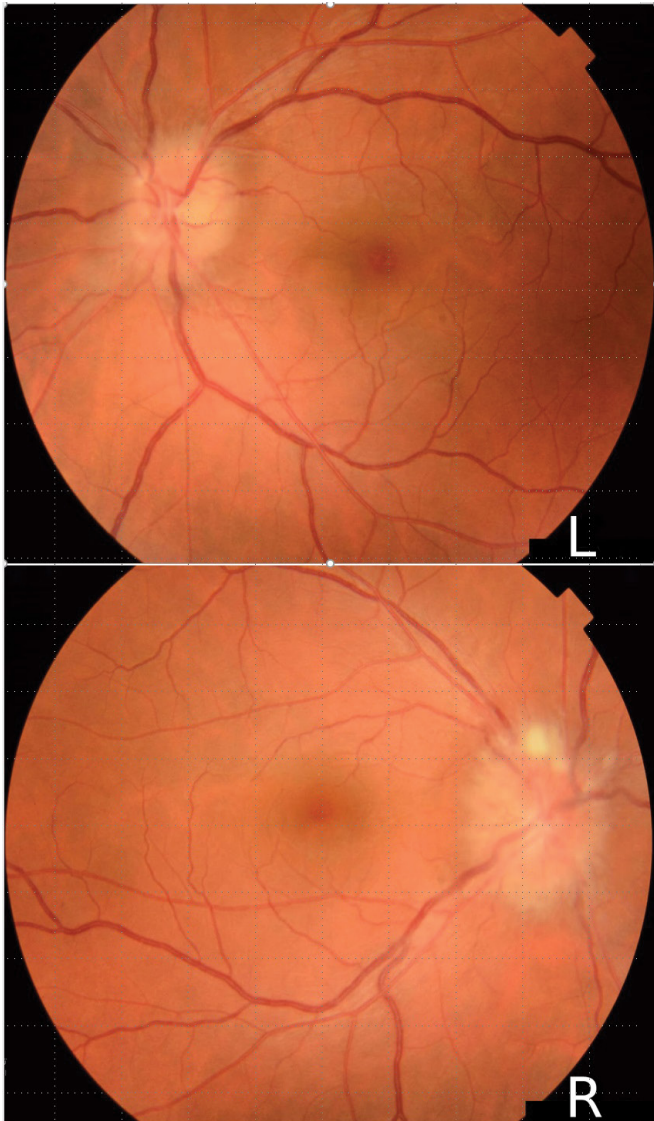In this paper, we report the case of acute myelitis associated with uveitis occurring after COVID-19 infection. Mechanism and treatment of neurologic manifestations are discussed.

### Case Report

A 32-year-old woman was admitted for gait disorder, vesico-sphincter disorder and visual blurring evolving for 2 weeks. These symptoms appeared four days after PCR proven infection with coronavirus 19. The evolution was marked by progressive worsening of walking, becoming ataxic and unstable, confining the patient to bed. On the other hand, the visual blur has gradually regressed spontaneously. The patient was admitted in

the neurologic unit and the clinical examination showed ataxic walking, unstable standing position, motor deficit and hypoesthesia in both lower limbs. Reflexes are abolished and there is a suspended sensory level at C2- C3 to superficial tact and pinprick testing. Otherwise, there is no cerebellar syndrome or cranial nerves damage. The patient reported also urinary retention but the perineal examination was without abnormalities. Ophthalmologic examination found bilateral papilledema stage 2 and intermediate uveitis (**Figure 1**). The Cerebrospinal Fluid (CSF) analysis was normal. The serological testing of herpes simplex virus (type 1 and 2), Epstein Barr virus, cytomegalovirus, human immunodeficiency virus and hepatitis was negative.

Autoimmune tests were negative especially antinuclear, aquaporin 4 antibodies and anti-Myelin oligodendrocytes glycoprotein (MOG). The diagnosis of myelitis post COVID-19 was highly suggested. Brain MRI was normal and spinal MRI showed diffuse high T2 signal throughout the cervical, thoracic, and lumbosacral cord (**Figure 2A**). After gadolinium injection there is enhancement of the entire spinal cord (**Figure 2B**). The patient was treated with intravenous methylprednisolone (MP) 1 gram per day for 5 days and then full dose oral corticosteroid therapy with gradual reduction. The evolution was marked by the total regression of the motor deficit and the visual blur after 2 months.



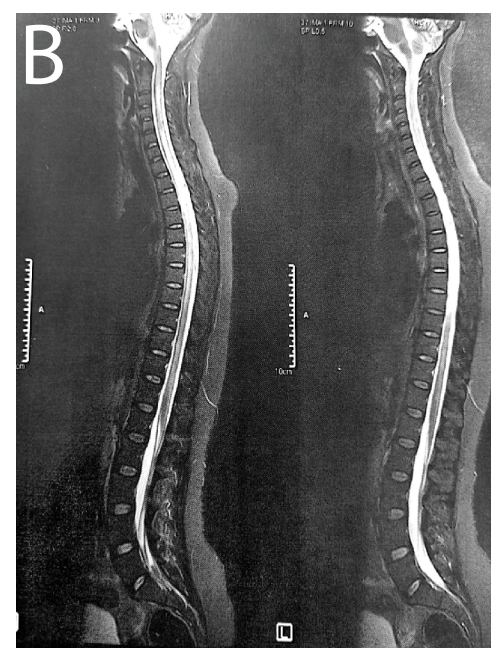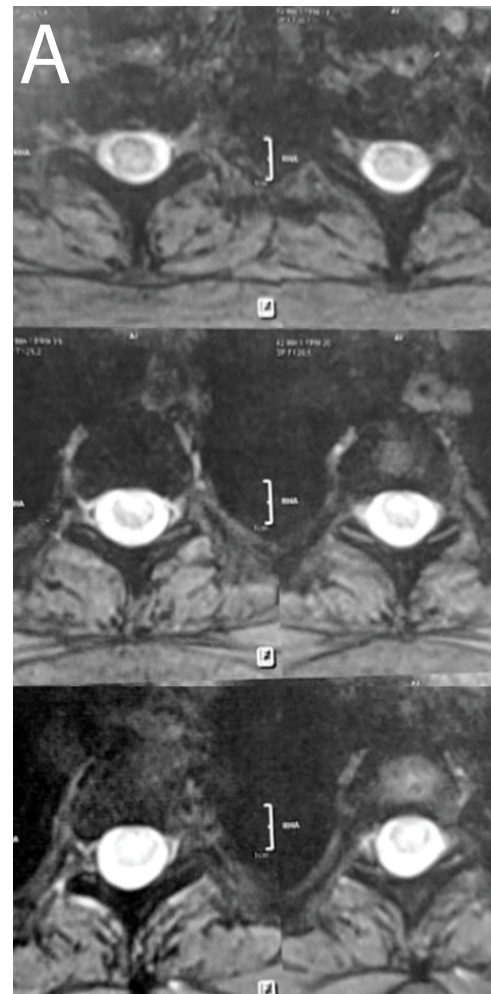
**Figure 1** Fundus examination showing bilateral papillary edema stage 3.

The repeated ophthalmologic examination showed a regression of the papillary edema passing to stage 1.

## Discussion

In this paper we have presented a case of acute myelitis associated with uveitis after recent COVID-19 infection. It is well known that SARS-CoV-2 has a neurotropism with commonly nonspecific neurologic complications as headache, myalgia, fatigue and vomiting. Severe neurologic symptoms are rarely reported. Among the Central Nervous System (CNS) features, acute stroke is most frequently reported. Seizures, encephalitis and myelitis are less described but being increasingly documented. Among the peripheral nervous system Guillain Barre syndrome has mostly been seen [1,2].

A Houston Methodist-led team of researchers have found COVID-19 can result in an unexpectedly frequent occurrence of Acute Transverse Myelitis (ATM), a rare but often devastating



**Figure 2** Sagittal (a) and axial (b) T2 weighted MRI showing high-signal intensity throughout the cervical, thoracic and lumbosacral cord.

spinal cord disorder. The team's study of documented pandemic cases found that 43 ATM involved an inflammation of the spinal cord that prevents sensory and motor information from flowing to the brain and the rest of the body. The cases occurred in both developed and underdeveloped countries [3].

Several possible mechanisms exist by which SARS-CoV-2 could lead to spinal cord manifestations. Coronaviruses have been shown to be both neuroinvasive and neurovirulent and can lead to demyelination and as well as an inflammatory response [4]. Since we did not detect SARS-CoV-2 RNA in the CSF of our patient, we postulate that it would likely be due to an immune-mediated inflammatory process rather than direct invasion of SARS-CoV-2 into the CNS. There are papers that emphasize a positive RT-PCR test for SARS-CoV-2 in CSF in the context of encephalitis, which is not a common finding in other COVID-19 neurological manifestations. These results highly suggest that there should be other explanations for neurological symptoms associated with COVID-19 disease [5,6].

To our knowledge, there is no evidence-based treatment guidelines available for para-infectious ATM. If a para or post-infectious pathogenesis is corroborated, intravenous immunoglobulins (IVIg) may be another treatment option [4]. Concerning our patient, a spectacular improvement was the rule under corticosteroid therapy.

Coronaviruses are known to cause various ocular infections in animals such as conjunctivitis, anterior uveitis, retinitis, and optic neuritis. Bettach E et al. [7] presented recently a case of COVID-19 that presented initially to ophthalmology clinic with

keratoconjunctivitis with small pseudo dendrite and small subepithelial infiltrates in the cornea. It is well known that SARS-CoV-2 induces conjunctivitis. A study conducted on 38 COVID-19 infected patients showed that 5% of them had virus-positive conjunctivitis and 32% had conjunctivitis. Moreover, retinal hemorrhages, central retinal vein occlusion and other retinal thrombotic complications have been observed in COVID-19 patients [8]. Intermediate post COVID-19 uveitis is very rarely described in the literature so far. The stasis papillary edema would be due to viral infection and not by intracranial hypertension since the opening pressure at the lumbar puncture was normal as well as the cerebral MRI. The improvement of edema and uveitis by corticosteroid therapy supports this argument.

All physicians should keep in mind the possibility of uveitis in the differential diagnosis when dealing with patients who had previous viral prodromal symptoms up to a few weeks prior to presenting with uveitis [8,9]. To the best of our knowledge, no case of myelitis associated with post-COVID-19 intermediate uveitis has been reported before.

## Conclusion

Coronavirus remains a virus like all viruses that can cause post-infectious myelitis but the prevalence, severity and prognosis of post-COVID-19 myelitis remains to be determined. Thus, it is of major importance to remain cognizant of the atypical and less-prevalent sequelae of viral infections in patients with recent COVID-19 infection, as prompt recognition and management are important to prevent significant morbidity.

## References

- 1 Yavarpour-Bali H, Ghasemi-Kasman M (2020) Update on neurological manifestations of COVID-19. *Life Sci* 15: 118063.
- 2 Nepal G, Rehrig JH, Shrestha GS, Shing YK, Yadav JK, et al. (2020) Neurological manifestations of COVID 19: A systematic review. *Crit Care* 13: 421.
- 3 Román GC, Gracia F, Torres A, Palacios A, Gracia K, et al. (2021) Acute Transverse Myelitis (ATM): Clinical review of 43 patients with COVID-19-associated ATM and 3 post-vaccination ATM serious adverse events with the ChAdOx1 nCoV-19 vaccine (AZD1222). *Front Immunol* 12: 653786.
- 4 Schulte EC, Hauer L, Kunz AB, Sellner J (2021) Systematic review of cases of acute myelitis in individuals with COVID-19. *Eur J Neurol* 28: 3230-3244.
- 5 Águila-Gordo D, Flores-Barragán JM, Ferragut-Lloret F, Portela-Gutierrez J, LaRosa-Salas B, et al. (2020) Acute myelitis and SARS-CoV-2 infection. A new etiology of myelitis? *J Clin Neurosci* 80: 280-281.
- 6 Munz M, Wessendorf S, Koretsis G, Tewald F, Baegi R, et al. (2020) Acute transverse myelitis after COVID-19 pneumonia. *J Neurol* 267: 2196-2197.
- 7 Bettach E, Zadok D, Weill Y, Brosh K, Hanhart J (2021) Bilateral anterior uveitis as a part of a multisystem inflammatory syndrome secondary to COVID-19 infection. *J Med Virol* 93: 139-140.
- 8 Iriqat S, Yousef Q, Ereqat S (2021) Clinical profile of COVID-19 patients presenting with uveitis. A short case series. *Int Med Case Rep J* 14: 421-427.
- 9 Hung JCH, Li KKW (2020) Implications of COVID-19 for uveitis patients: Perspectives from Hong Kong. *Eye (Lond)* 34: 1163-1164.