

Jugular Foramen Meningioma Manifesting as Jackson Syndrome

Pedro Felipe Camelo Correa Alves Ferreira e Silva*, Gustavo Ferreira Martins, Eduardo Augusto Guedes de Souza, Renato Miguel Rezende, Karine Cim Assenço, Yuri José Almeida da Silva, Marcelo Ferraz de Campos and José Carlos Rodrigues Junior

Department of Neurosurgery, Complexo Hospitalar Heliópolis, São Paulo, Brazil

***Corresponding author:**

Pedro Felipe Camelo Correa Alves Ferreira e Silva

✉ pedrofelipeferreira@hotmail.com

Department of Neurosurgery, Complexo Hospitalar Heliópolis, São Paulo, Brazil.

Tel: +55 11 941602568

Citation: Silva PFCCAF, Junior JCR, Campos MF (2021) Jugular Foramen meningioma Manifesting as Jackson syndrome. J Neurol Neurosci ol.12 No 12:404

Abstract

Background: Jugular foramen meningiomas are quite exceptional. However, there are a few cases reported in literature. In this topography, they can be mistaken for other tumors, such as schwannomas or paragangliomas. Due to cranial nerve compression, Jackson's syndrome is a possible clinical manifestation.

Case description: We attended to a 58-year-old female who presented unilateral paresis of cranial nerves X to XII. Her MRI showed a solid lesion located in the right jugular foramen. A retro sigmoid craniotomy with subtotal gross resection was performed. Histopathology confirmed a meningothelial meningioma.

Conclusion: Jugular foramen meningiomas are rare, but as demonstrated in our report, should be included in a differential diagnosis of lesions in this topography. Treatments range from expectant to surgery and radiosurgery.

Keywords: Jugular foramen meningioma; Jackson syndrome; Meningioma; Retrosigmoid craniotomy

Received: November 18, 2021; **Accepted:** December 01, 2021; **Published:** December 07, 2021

Introduction

Meningiomas are extra-axial tumors and represent the most common tumor in the meninges. They comprise 20% of all primary Central Nervous System (CNS) tumour [1]. They are slow growing and have a good overall prognosis. Their most common location is in the brain convexity, with 6-15% in the posterior fossa [2]. In this topography, they could be located at the cerebellopontine angle, foramen magnum, clivus, petroclival region, tentorium, cerebellar convexity or jugular foramen. The latter topography is very rare [3].

When in the jugular foramen, they can be confused with other tumors, such as schwannomas or paragangliomas [4]. Gross total resection may lead to serious neurological sequelae, representing a surgical challenge due to the intricate relationship with the temporal and occipital bones, cranial nerves, arteries and veins intersecting within the region. In this context, Jackson syndrome comprises a rare constellation of symptoms caused by unilateral paresis of cranial nerves X to XII. This is caused by neoplastic or non-neoplastic lesions in the jugular foramen that extend to the hypoglossal canal or nerve. Our aim is to present a case of this rare tumoral entity associated with an unusual clinical syndrome.

Case Report

We attended to a 58-year-old female who presented to our facility, complaining of a six year right-sided tinnitus, which gradually evolved into a right-sided headache and hearing loss. The patient has a history of arterial hypertension and dyslipidemia. Upon hospital admission, examinations revealed a Glasgow Coma Scale of 15, right-sided palate paresis, and hypotrophy of the right trapezius. In addition to a right-sided anasacosis, dysphonia and fasciculations in the right half of the tongue were discovered. Her sense of taste was unaffected, and the examination of other systems was normal. An initial contrast-enhanced brain MRI revealed a right-sided solid expansive

lesion, centered on the jugular bulb and cochlear promontory, with an isosignal on T1 and mild hypersignal on T2. There was bone erosion in the adjacent mastoid. The lesion extended to the cerebellopontine angle, entering into the hypoglossal canal, and compressing part of the sigmoid sinus and right superior jugular vein. It also encompassed the posteroinferior cerebellar artery for approximately 270° (Figure 1). A preoperative CT angiogram showed incomplete occlusion of the right jugular bulb and internal jugular vein (Figure 2). We proposed the patient to undergo a surgical treatment, through a retrosigmoid approach. Due to the risk of cranial nerve lesion, we preferred a subtotal gross resection. So, intraoperatively, the lesion that occupied the cerebellopontine angle, internal acoustic meatus and part of the jugular foramen was removed. The cranial nerves were preserved, but there was intense manipulation. A portion of the tumor that was located inside the jugular foramen and in the extracranial compartment outside of the jugular foramen wasn't removed to avoid greater surgical morbidity. In the postoperative period, we observed: reagravated hearing loss, right-sided palate palsy, House-Brackman grade II peripheral facial palsy, dysphagia, paresis in right eye abduction, and nystagmus with a rapid phase to the right. During outpatient follow-up, she experienced progressive improvement. Two months after the procedure, she returned to her clinical status prior to surgery. Histopathology confirmed the suspicion of meningotheial meningioma (Figure 3). The postoperative MRI showed a residual lesion outside the jugular foramen (Figure 4). Subsequently, the patient required and underwent an adjuvant stereotaxic radiosurgery.

Discussion

Meningiomas are benign tumors that originate from the arachnoid cap cells. They constitute the outer layer of the arachnoid villi with cytological similarities resembling meningioma cells. These are likely their origin [2]. In the jugular foramen, they are extremely rare. There have been just a few cases reported in literature. The first series of meningioma published by Ruggiero [2] and Cushing [4] didn't even mention them. Al-Mefty called them jugular fossa meningiomas to differentiate them from meningiomas that extend to the jugular foramen, without primarily originating there [5,6]. They most likely come from the villi associated with the jugular bulb [1,7]. The jugular foramen, located between the occipital bone and the petrous bone, is a bone canal divided into two parts (vascular and nerve) separated by a fibrous septum. It

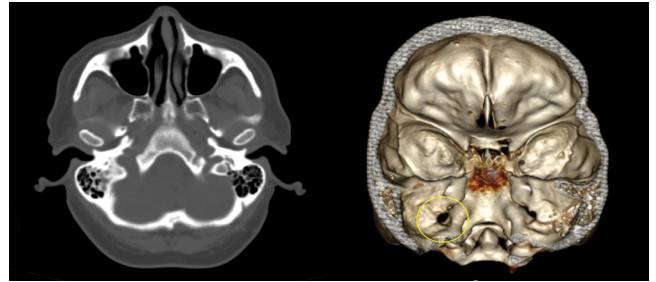


Figure 2 CT showing widening of jugular foramen.

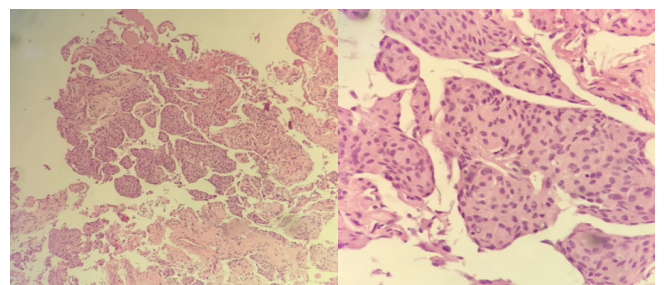


Figure 3 Histopathological sections with 40X and 100X magnification, left and right respectively, show cells with abundant, pink cytoplasm resembling epithelial cells. As the boundaries are imprecise, they may resemble syncytia (origin of the term 'syncytial meningioma').

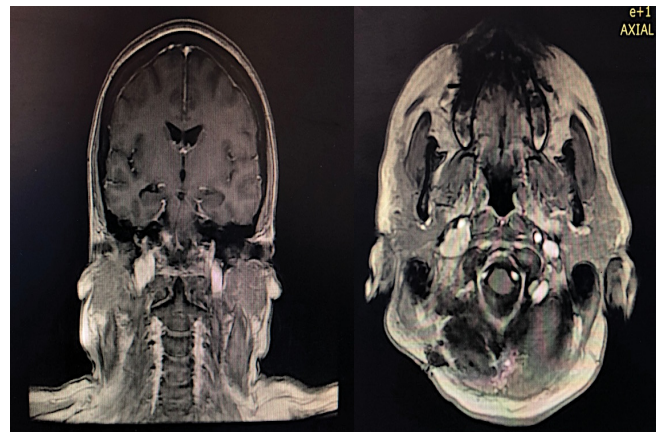


Figure 4 Postoperative MRI showed a residual lesion outside the jugular foramen.

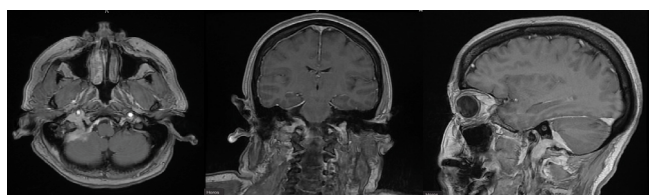


Figure 1 Contrast-enhanced T1-weighted MRI of the brain in the axial, coronal and sagittal sections demonstrates a lesion in the right jugular foramen, extending to the internal auditory meatus, cerebellopontine angle, and extracranially.

contains the IX, X, XI cranial nerves. It also includes the jugular vein and meningeal branches of the ascending and occipital pharyngeal arteries [1,4,8]. Tumors in this region can adopt three directions: anterior to the jugular bulb, posterior to the jugular bulb, or completely occluding it. They can also occupy the posterior fossa or extend extra cranially. Jackson syndrome is defined as unilateral palsy of the inferior cranial nerves X-XII. Initially described by Hughlings Jackson in 1864 as unilateral paralysis of the soft palate, larynx, sternocleidomastoid, trapezius, and tongue. It is a very rare condition that results from lesions at

the base of the skull which affect both the jugular foramen and the hypoglossal canal. The main cause is a tumor, benign (such as meningiomas) or malignant lesions.

Clinical manifestations

Depending on tumor location and size, symptoms include hearing loss, dizziness, tinnitus, headache, dysphonia, gait abnormalities, dysphagia, or a combination of all of them. Vernet's Syndrome occurs when there is involvement of the IX, X, XI nerves, characterized by loss of taste in the posterior third of the tongue, paralysis of the vocal cords and palate, paresis of the trapezius and sternocleidomastoid muscles. Collet-Sicard Syndrome, on the other hand, is a combination of paresis of these last nerves, associated with paresis of the XII nerve, showing tumor extension to the hypoglossal canal [9]. Our case report fills all features of Jackson's syndrome. Some report tell us that a unilateral XII nerve palsy is facultative, but the majority of them say it's a mandatory criteria, as originally described by Hughlings Jackson [3,10].

Characteristics images

Jugular foramen meningiomas tend to infiltrate the skull base, involving the hypoglossal canal, internal acoustic meatus, clivus, posterior fossa, carotid space, and may even reach the middle ear. Extracranial extensions are limited to the carotid-nasopharyngeal space, in the suprahyoid region. In MRI, it maintains the typical characteristics of meningiomas, which are iso/hypointense on T1, iso/hypertensive on T2, with intense homogeneous contrast enhancement. In CT, the cortical bone may show irregularities, maintenance of bone density and architecture [6] hyperostosis or even destruction of the walls in the jugular foramen [1]. Angiography, CT angiogram or magnetic resonance angiogram are essential in preoperative programming, in order to study jugular vein and the degree of invasion of the internal carotid artery. Angiography is imperative in cases of

preoperative embolization, despite its debatable use in these cases [1,8]. Differential diagnoses include the aforementioned paragangliomas and schwannomas, but also epidermoid tumors, chordomas, aneurysms, and metastases. Paragangliomas usually erode bone and rarely have calcifications. Schwannomas are slightly hyperdense and widen the jugular foramen, but without bone destruction or hyperostosis [11,12].

Treatment

Treatment ranges from expectant, surgery or radiosurgery, or combination of them. The most cited surgical approaches in literature are suboccipital retromastoid [1,8] or infratemporal [7,9] (Described by Fisch and later by Al-Mefty), and transcondylar craniectomy with sigmoid sinus ligation at the level of the jugular bulb [7] Subtotal resection is the most common result [1,4,5,7,11]. Prior to surgery, we thought it was a vagal schwannoma. especially because of a widening in the jugular foramen. However, intraoperative findings (such as aspect, texture, relationship with duramater) warned us we could be dealing with this uncommon localization of meningioma. As depicted above, we preferred a subtotal gross resection to avoid any other injury to the nerves near the tumor and jugular foramen. Among all tumors that cause of jugular foramen syndromes, paragangliomas and schwannomas are the most common. Meningiomas remain so rare that even Cushing didn't describe them in his series. Adjuvant therapies such as stereotaxic radiosurgery complete the patient's treatment when there are residual injuries.

Conclusion

Although rare, jugular foramen meningiomas, as demonstrated in our report, should be included in the differential diagnosis of lesions in this topography. The purpose of this publication is to raise the level of suspicion in this specific area and improve surgical planning and operative results.

References

- 1 Arnautović KI, Al-Mefty O (2002) Primary meningiomas of the jugular fossa. *J Neurosurg* 1;97:12-20.
- 2 Castellano F (1953) Meningiomas of the posterior fossa. *Acta Radiol Suppl (Stockh)* 104:1-57.
- 3 Das JM, Al Khalili Y (2021) Jugular Foramen Syndrome. *StatPearls* 9.
- 4 Eisenhardt L, Cushing H (1938) Meningiomas: Their classification, regional behaviour, life history, and surgical end results. *Bulletin of the Medical Library Association* 27:185.
- 5 Nowak A, Dzedzic T, Czernicki T, Kunert P, Marchel A (2014) Surgical treatment of jugular foramen schwannomas. *Neurologia i Neurochirurgia Polska*. 48:188-195.
- 6 Ríos RG, Sanz AC, Polo CG, García MIZ, Sánchez-Mateoset ,et al.(2015) Collet-Sicard syndrome. *Neurologia* 30:130–134.
- 7 Rajesh U, Bisht A, Shijith KP, Shukla A (2015) A rare case of jugular foramen meningioma. *Med J Armed Forces India* 72:S192.
- 8 Ogasawara C, Philbrick BD, Adamson DC. (2021) Meningioma: A review of epidemiology, pathology, diagnosis, treatment, and future directions. *Biomedicine* 9:319.
- 9 Siqueira MG (2015) Tratado de Neurocirurgia da Sociedade Brasileira de Neurocirurgia. 1a., Siqueira MG (ed), Manole.
- 10 Horgan JB (1942) The Jugular or Hughlings Jackson Syndrome. *J Laryngol* 57:489-490.
- 11 Ramina R, Maniglia JJ, Fernandes YB, Paschoal JR, Pfeilsticker LN, et al. (2004) Jugular foramen tumors: Diagnosis and treatment. *Neurosurg Focus*. 17:31-40.
- 12 salzman kl, harnsberger hr, gilbert e, shelton c (2004) primary jugular foramen meningioma: Imaging appearance and differentiating features. *Am JRoentgenol* 373–377.