

## The Prevalence of Unruptured Cerebral Aneurysms in Okinoerabu: A Japanese Hospital-Based Study

Hisashi Ito<sup>1</sup>,  
Tazuyo Kawaminami<sup>2</sup>,  
Kayo Asano<sup>2</sup>,  
Tomoko Fukunaga<sup>3</sup>,  
Kiyomi Edura<sup>4</sup>,  
Chiseko Karai<sup>4</sup>,  
Satsuki Okuma<sup>4</sup>,  
Sachiko Takeshita<sup>5</sup>,  
Motokazu Tsutsumi<sup>5</sup>,  
Yoshihiro Tokeshi<sup>6</sup> and  
Tetsuya Itagaki<sup>7</sup>

### Abstract

**Background:** Unruptured cerebral aneurysms (UCAs) might lead to a poor outcome. However, the previously reported prevalence of UCAs in Japan ranges widely.

**Method:** The objects of this retrospective and hospital-based study were adult residents of Okinoerabu, a small island in Japan. We performed the examination of the brain with 1.5-Tesla MR angiography (MRA) from December 2017 to May 2018 at Okinoerabu Tokushukai Hospital. We estimated the prevalence of UCAs and investigated the characteristics of UCAs.

**Results:** Thirty UCAs were found in 27 of 356 persons. 3 persons had multiple UCAs. The overall prevalence was 7.6% (Men 7.3%; Women 7.8%). Except for one person, UCAs were identified in those over 50 years old and women in 5th decade showed the highest prevalence (14.3%). More than half of UCAs located in the internal carotid artery (ICA, 56.7%). Most UCAs had a maximum diameter less than 4.9 mm (93.3%).

**Conclusion:** The overall prevalence of UCAs in Okinoerabu was comparatively high on Okinoerabu. The characteristics of UCAs were as follows: over 5th decade, in ICA, and smaller than 4.9 mm.

**Keywords:** Unruptured cerebral aneurysms; Prevalence; MR Angiography

**Received:** September 19, 2018; **Accepted:** October 25, 2018; **Published:** October 29, 2018

### Introduction

Most unruptured cerebral aneurysms (UCAs) are asymptomatic and we often identify them incidentally; however, it is important to detect UCAs by various techniques to prevent subarachnoid hemorrhage. In this study, we investigated the prevalence of UCAs on Okinoerabu, a small island in Japan, using MR angiography (MRA) with 1.5-Tesla MRI.

### Materials and Methods

This was a retrospective study of adult residents of Okinoerabu who underwent examination of the brain using MRA, called 'Brain Dock'. The examination was performed at Okinoerabu Tokushukai Hospital from December 2017 to May 2018. The Review Board of Okinoerabu Tokushukai Hospital Ethics Committee approved this study. Distributions of the age and sex are shown in **Table 1**. We collected their past medical histories including smoking, hypertension, diabetes, and hyperlipidemia.

- 1 Department of Neurology, Shonan Fujisawa Tokushukai Hospital, Fujisawa, Japan
- 2 Healthcare Center, Okinoerabu Tokushukai Hospital, China, Japan
- 3 Department of Rehabilitation, Okinoerabu Tokushukai Hospital, China, Japan
- 4 Department of Nursing, Okinoerabu Tokushukai Hospital, China, Japan
- 5 Department of Radiology, Okinoerabu Tokushukai Hospital, China, Japan
- 6 Department of Internal Medicine, Okinoerabu Tokushukai Hospital, China, Japan
- 7 Department of Neurosurgery, Naze Tokushukai Hospital, Amami, Japan

\*Corresponding author: Hisashi Ito

✉ hisashi.ito@tokushukai.jp

Department of Neurology, Shonan Fujisawa Tokushukai Hospital, 251-0041, Fujisawa, Japan.

Tel: +81-466-35-1177

**Citation:** Ito H, Kawaminami T, Asano K, Fukunaga T, Edura K, et al. (2018) The Prevalence of Unruptured Cerebral Aneurysms in Okinoerabu: A Japanese Hospital-Based Study. J Neurol Neurosci Vol.9 No.5:273.

**Table 1** The age- and sex-distribution and the prevalence of UCAs in 10-year age groups.

Variables	Men		Women	
	Age range (yr)	No of persons	No of UCAs+	No of persons
20~29	3	0 (0%)	4	0 (0%)
30~39	8	1 (12.5%)	11	0 (0%)
40~49	11	0 (0%)	16	0 (0%)
50~59	13	1 (7.7%)	27	4 (14.8%)
60~69	41	2 (4.9%)	89	8 (9.0%)
70~79	38	4 (10.5%)	62	4 (6.5%)
80~	10	1 (10.0%)	23	2 (8.7%)
Total	124	9 (7.3%)	232	18 (7.8%)

We performed multislab 3-dimensional time-of-flight MRA of the brain (repetition time, TR 28.0 msec; echo time, TE 7.0 msec; thickness 0.6 mm) using a 1.5-Tesla MRI (Magnetom Essenza, Siemens Healthcare K.K.). Neuroradiologically experienced neurologist and neurosurgeon interpreted MRA. UCAs that were 2.0 mm or more in their largest dimension were included in the study. On the other hand, we excluded fusiform or dissecting aneurysms from the analysis because of differences in pathological origins. We evaluated the overall, age-specific, and sex-specific prevalence.

We classified the locations of UCAs as: internal carotid artery (ICA), middle cerebral artery (MCA), anterior cerebral artery (ACA, including the anterior communicating artery), posterior cerebral artery (PCA, including the posterior communicating artery), and vertebrobasilar artery (VA-BA). In addition, we classified UCAs into five size categories (less than 3.0 mm, 3.0 to 4.9 mm, 5.0 to 6.9 mm, 7.0 to 11.9 mm, and more than 12.0 mm).

The chi-square test and Mann-Whitney U-test were used for statistical analysis. All P-values were two-sided and considered significant if they were 0.05 or less.

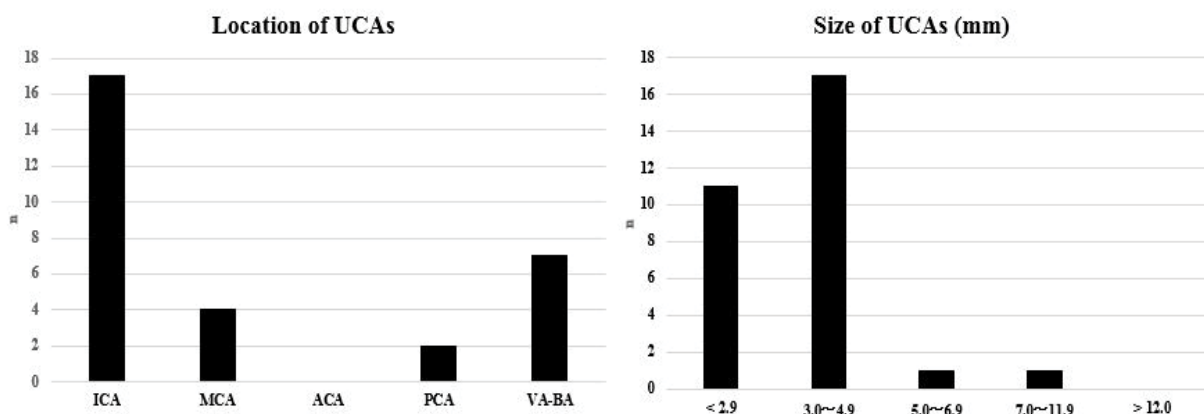
## Results

Thirty UCAs were identified in 27 of 356 persons (Men 124; Women 232; 22 to 91 years, 63.9 ± 13.3 years). Among them, multiple UCAs were discovered in 3 persons. The overall prevalence was 7.6% with 7.3% for men and 7.8% for women. UCAs were identified in those aged over 50 except for one person (96.3%). The prevalence of UCAs increased with age in men, and it was the highest in the 5th decade in women (14.8%). There was no significant difference in age, sex, smoking, or comorbidity between the groups with and without UCAs (Tables 1 and 2). The most common location of UCAs was ICA (56.7%), followed by VA-BA (23.3%). The most common maximum diameter was 3.0 to 4.9 mm (56.7%), and most of the UCAs were less than 4.9 mm (93.4%) (Figure 1).

**Table 2** The comparison between UCAs group and non-UCAs group.

Characteristics	UCAs+ (n=27)	UCAs- (n=329)	Total (n=356)	p value
Mean Age (yr)	67.5 ± 11.4	63.6 ± 13.5	63.9 ± 13.3	0.322*
Men / Women (n)	9 / 18	115 / 214	124 / 232	0.968**
Smoking (n)	5 (18.5%)	80 (24.3%)	85 (23.9%)	0.657**
Hypertension (n)	12 (44.4%)	137 (41.6%)	149 (41.9%)	0.777**
Diabetes (n)	0 (0%)	36 (10.9%)	36 (10.1%)	NE***
Hyperlipidemia (n)	2 (7.4%)	64 (19.5%)	66 (18.5%)	NE***

\*Chi-square test; \*\*Mann-Whitney U-test; \*\*\*not examined as numbers were too small.



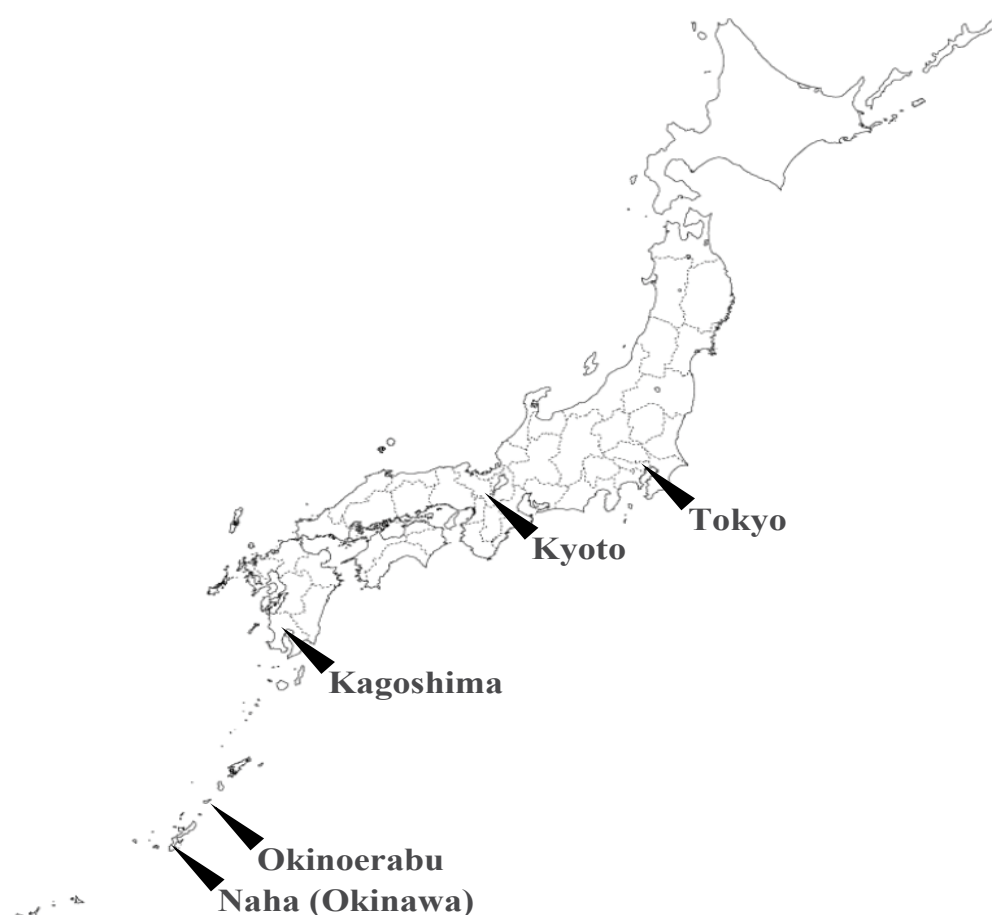**Figure 1** The distribution of UCAs locations and sizes.

## Discussion

Okinoerabu is a small island located in the south-west of Japan, and the approximate adult population is 10,000 [1] (**Figure 2**). Both transportation and medical resources are limited. MR imaging was available only at Okinoerabu Tokushukai Hospital during the study period.

The previously reported prevalence of UCAs in Japan varied widely (**Table 3**) [2-8]. Ujiie et al. first reported the prevalence of UCAs as 2.7% [2]. Three studies after this one revealed a similar prevalence [4,5,7], while other studies demonstrated a higher prevalence, 4.3% to 8.4% [3,6,8]. They were evaluated by

angiography [2,3], autopsy [4], and MRA [3,5-8]. The prevalence of UCAs in angiography studies tended to be higher than that in autopsy and MRA studies [9,10]. On the other hand, Gibbs et al. reported that MRA with 1.5-Tesla and 3-Tesla MR systems could demonstrate all aneurysms that had already been identified by angiography [11]. Recently, MRA has become the most popular tool to detect UCAs as it is a non-invasive and repeatable procedure. A high-tesla MR system could provide better image quality, leading to a higher rate of UCA detection [6,11]; however, the prevalence of UCAs in our study was higher than that using MRA with a 3-Tesla MR system [8]. Therefore, the magnetic field intensity and detection rate of UCAs might not be correlated.



**Figure 2** Location of Okinoerabu.

**Table 3** Previous epidemiological study of UCAs from Japan.

Author	Ujiie H et al. [2]	Nakagawa T et al. [3]	Iwamoto H et al. [4]	Horikoshi T et al. [5]	Igase K et al. [6]	Harada K et al. [7]	Imaizumi Y et al. [8]	Our study
No of objects	1612	400	1230	4518	3414	8696	4070	356
Method	Angiography	Angiography + MRA	Autopsy	MRA (0.5 T)	MRA (3 T)	MRA (1.5 T)	MRA (3 T)	MRA (1.5 T)
Prevalence	2.7%	6.5%	2.2%	2.8%	8.4%	3.2%	4.3%	7.6%
Common location	ICA	ICA	MCA	MCA	ICA	ICA	ICA	ICA
Common size	less than 6.0 mm	less than 5.0 mm	ND**	2.0 to 4.9 mm	3.0 to 4.9 mm	2.0 to 4.9 mm	2.0 to 2.9 mm	3.0 to 4.9 mm

\*Magnetic flux density was not described; \*\*Not described.

Except for one study [3], the prevalence in women was higher than that in men [2,4-8], which is similar to our results. In addition, several studies from Japan demonstrated that the prevalence of UCAs increased with age [2,5,7,8], and we also recognized this trend in men. We might have to take the age distribution of each study into consideration when evaluating the prevalence of UCAs.

□Regarding the characteristics of UCAs, both the location and size in our study were similar to those of previous reports from Japan [2,3,6-8], except for the prevalence of VA-BA aneurysms. One advantage of our study is its limited bias because it was performed in a relatively isolated environment.

On the other hand, the limitation of this study is a small size. We have to continue this investigation with more persons to fully consider the characteristics of UCAs on Okinoerabu.

## References

- 1 <http://www.pref.kagoshima.jp/ac09/tokei/bunya/kokutyo/h27kokutyo/h27jinnkoutoukihonnshyuukeinenreibetujinnkou.html>
- 2 Ujiie H, Sato K, Onda H, Oikawa A, Kagawa M, et al. (1993) Clinical analysis of incidentally discovered unruptured aneurysms. *Stroke* 24: 1850-1856.
- 3 Nakagawa T, Hashi K (1994) The incidence and treatment of asymptomatic, unruptured cerebral aneurysms. *J Neurosurg* 80: 217-223.
- 4 Iwamoto H, Kiyohara Y, Fujishima M, Kato I, Nakayama K, et al. (1999) Prevalence of intracranial saccular aneurysms in a Japanese community based on a consecutive autopsy series during a 30-year observation period. The Hisayama study. *Stroke* 30: 1390-1395.
- 5 Horikoshi T, Akiyama I, Yamagata Z, Nukui H (2002) Retrospective analysis of the prevalence of asymptomatic cerebral aneurysm in 4518 patients undergoing magnetic resonance angiography - When does cerebral aneurysm develop? *Neurol Medico-Chirurgica (Tokyo)* 42: 105-112.
- 6 Igase K, Matsubara I, Igase M, Miyazaki H, Sadamoto K (2012) Initial experience in evaluating the prevalence of unruptured intracranial aneurysms detected on 3-Tesla MRI. *Cerebrovasc Dis* 33: 348-353.
- 7 Harada K, Fukuyama K, Shirouzu T, Ichinose M, Fujimura H, et al. (2013) Prevalence of unruptured intracranial aneurysms in healthy asymptomatic Japanese adults: differences in gender and age. *Acta Neurochir (Wien)* 155: 2037-2043.
- 8 Imaizumi Y, Mizutani T, Shimizu K, Sato Y, Taguchi J (2018) Detection rates and sites of unruptured intracranial aneurysms according to sex and age: an analysis of MR angiography-based brain examinations of 4070 healthy Japanese adults. *J Neurosurg* 2018 Apr 6: 1-6.
- 9 Rinkel GJ, Djibuti M, Algra A, Van Gijn J (1998) Prevalence and risk of rupture of intracranial aneurysms: A systematic review. *Stroke* 29: 251-256.
- 10 Okahara M, Kiyosue H, Yamashita M, Nagatomi H, Hata H, et al. (2002) Diagnostic accuracy of magnetic resonance angiography for cerebral aneurysms in correlation with 3D-digital subtraction angiographic images: A study of 133 aneurysms. *Stroke* 33: 1803-1808.
- 11 Gibbs GF, Huston J 3rd, Bernstein MA, Riederer SJ, Brown RD Jr (2004) Improved image quality of intracranial aneurysms: 3.0-T versus 1.5-T time-of-flight MR angiography. *Am J Neuroradiol* 25: 84-87.

## Conclusion

The overall prevalence of UCAs was comparatively high on Okinoerabu. Most of the UCAs were identified in those over 50 years old. ICA was the most commonly affected region, and most UCAs were smaller than 4.9 mm.

## Acknowledgements

We thank Dr. Tatsuya Yagi (Department of Radiology, Shonan Fujisawa Tokushukai Hospital) and Dr. Tetsumasa Kamei (Department of Neurology, Shonan Fujisawa Tokushukai Hospital) for their advices to this study.